

## Dental Implants in Diabetic Patients - A Case Report

Abdulrahman Hunaish<sup>1</sup>, Sadeq Ali Al-Maweri<sup>2</sup>

<sup>1</sup>(Department Of Oral And Maxillofacial Surgery, Alfarabi Colleges, Riyadh, Saudi Arabia; Department Of Oral Surgery; Ibb University, Yemen)

<sup>2</sup>(Department Of Oral Medicine And Diagnosis, Alfarabi Colleges, Riyadh, Saudi; Department Of Oral Medicine, Sana'a University, Yemen)

---

**Abstract:** Implant treatment is an attractive substitute to the traditional prosthetic appliances. However, diabetes mellitus has long been considered a relative contraindication to dental implant therapy. In this case report, we present the results of an immediate implant placement in fresh extraction sockets of mandibular anterior teeth and the implantation of the edentulous posterior mandibular regions in a diabetic patient. A 60-year old male diabetic patient presented with severe mobile lower anterior teeth and edentulous posterior areas. Lower teeth were extracted and immediate implants were placed. Additionally, implantation of the edentulous posterior regions was carried out. The follow up period showed stability of the implants and confirmed a satisfactory treatment result.

**Keywords:** dental implants, diabetes, fresh extraction socket, immediate placement

---

### I. Introduction

Dental implantation is considered as one of the most widely employed procedures in dental practice (1). It is considered as an attractive substitute to the traditional fixed/removable prosthesis (2). The success rate of dental implants can be influenced by numerous Local and systemic factors. Systemic conditions cited to negatively influence the success rate of implants include osteoporosis, immune deficiency virus infection and diabetes mellitus (2).

Diabetes mellitus, a common metabolic disorder, is characterized by hyperglycemia resulting from defects in insulin secretion, insulin action, or both (3). There are two main types of diabetes, Type 1 and type 2 (4). Type 2 diabetes is associated with relative insulin deficiency and is the most common type of diabetes, accounting for 90% -95% of all diabetic subjects. Type 1 diabetes on the other hand is associated with pancreatic B cells destruction and accounts only for 5% to 10% of all diabetes cases (2, 4). Chronic hyperglycemia is associated with several microvascular and macrovascular alterations resulting in numerous systemic and oral complications (2, 5, 6). Systemic complications include, but not limited to, delayed wound healing, blindness, renal disease and cardiovascular disorders (2, 6). Oral complications reportedly associated with diabetes include, oral mucosal lesions, xerostomia, periodontitis and tooth loss (7). Given the fact that hyperglycaemia is associated with microvascular alterations, as noted above, subjects with diabetes usually have delayed wound healing and more prone to infection. Dental implant survival is initially dependent upon successful osseointegration following placement (5). The effect of diabetes on implant has revealed an alteration in bone remodeling and deficient mineralization resulting in poor osseointegration. Due to delayed wound healing and other issues affecting the osseointegration of dental implants, diabetes mellitus has been considered as a relative contraindication for dental implant therapy (2, 5). However, well-controlled diabetes patients can be considered as appropriate candidates for dental implants treatment. In this report we present and describe the results of dental implant procedure in a 60-year old male diabetic patient.

### II. Case Report

A 60 -year old Yemeni male patient presented to our clinic with the chief complaint of teeth mobility and difficulty of eating. Clinical and panoramic radiographic examination revealed a severe mobile lower anterior teeth (grade III) and edentulous posterior mandibular regions [Fig 1]. According to the medical history, the patient had diabetes mellitus type 2 for one year that has been controlled by diet. Laboratory investigations showed a good level of glycemic control (fasting blood sugar: 110-140 mg/dl; postprandial blood sugar: 160-190 mg/dl; HbA1c: 6.5%).

The patient was given a detailed explanation concerning the present state, alternative treatment plans and the proposed procedures. Treatment with implantation of the edentulous posterior mandibular regions together with extraction of lower anterior mobile teeth and immediate implant placement was planned. Pre-surgical implant planning was performed by using CT scan and Simplant program software to evaluate the height, width and density of bone. Also, the position of the inferior alveolar canal was detected [Fig 2].

The operation was performed under general anesthesia (GA) using nasoendotracheal intubation. The patient was given 1.5 gm Sulbactam / Ampicillin and Dexamethazone Naph 8 mg/ml IV preoperatively after

induction of GA. The patients was scrubbed and draped according to the regular surgical standards. Lidocaine local anesthesia, containing adrenaline 1: 100,000 was injected at the site of implant placement to decrease intraoperative bleeding.

After that, drilling and insertion of four implants ( 6X8 mmTSV,Zimmer,USA.of each) in the posterior regions was performed with the aid of surgical template. The occlusal surfaces of the posterior implants were grafted with bovine anorganic hydroxyapatite(Bio-Oss, Geistlich AG, Wolhusen,Switzerland) and covered with a resorbable collagen barrier membrane(Bio- Gide, Geistlich AG). Then, the anterior teeth were extracted and replaced immediately with five implants (3.7X16 mm of each). Primary closure was performed for all implants using 3/0 vicryl.

The patient was placed on augmentin 1 gm /day for 5 days, mefenamic acid 500 mg initially then mefenamic acid 250 mg 4/day for 5 days, and chlorhexidine digluconate 0.12% 3/day for 4 weeks. He was asked not to chew on the surgical area for the first 4 weeks postoperatively. The patient was instructed to maintain good oral hygiene. The initial postoperative period showed uneventful healing. Immediate postoperative panoramic radiograph showed acceptable implant placement with no injury of the inferior alveolar canal [Fig 3].

After 3 months, the submerged implants were exposed and the abutments were secured to the fixtures. After that, impression and master casts were obtained and mounted to a semi adjustable articulator. The abutments were prepared outside the mouth on the working cast. The working cast was then sent to the laboratory for fabrication of the fixed prosthesis (two bridge right and left). Immediately after loading, panoramic x-ray was obtained which showed considerable amount of bone resorption around the posterior implants only (Fig 4). Another panoramic x-ray was obtained two years after loading which showed minimal increase of bone resorption around the posterior implant [Fig 5]. On clinical examination, the two bridges were well maintained in function without any mobility.

### III. Figures

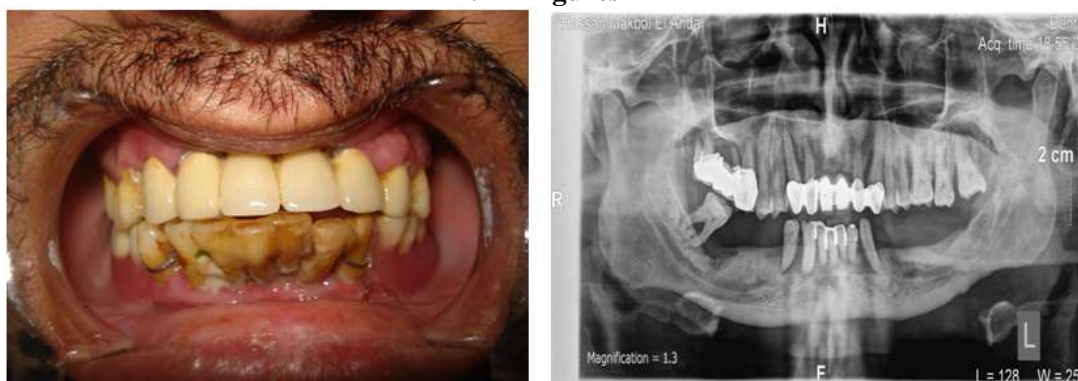

Figure 1: Preoperative photograph/radiograph showing the lower anterior teeth with sever bone resorption

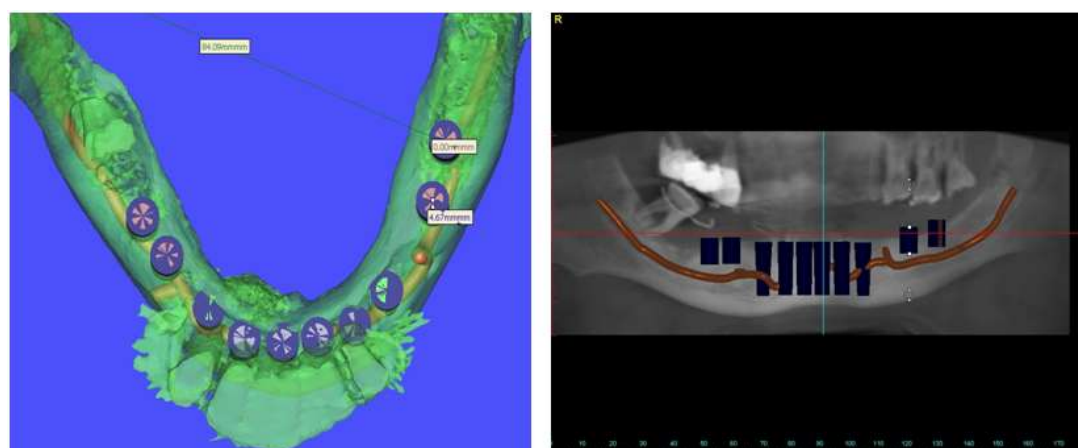
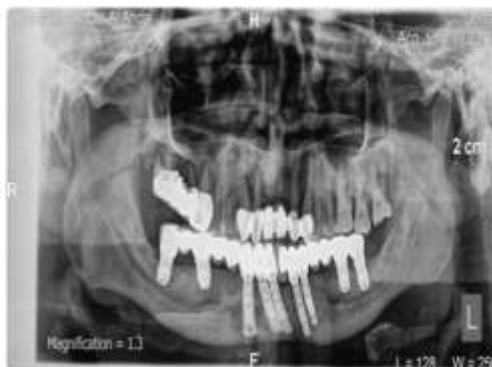
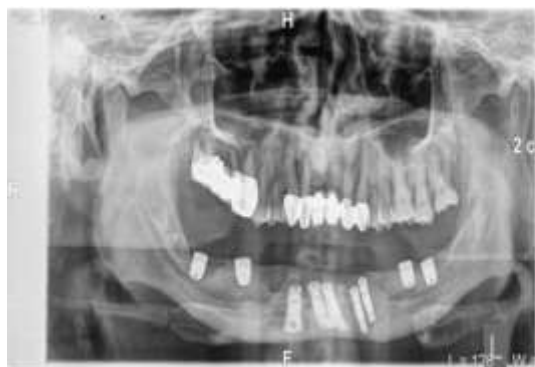
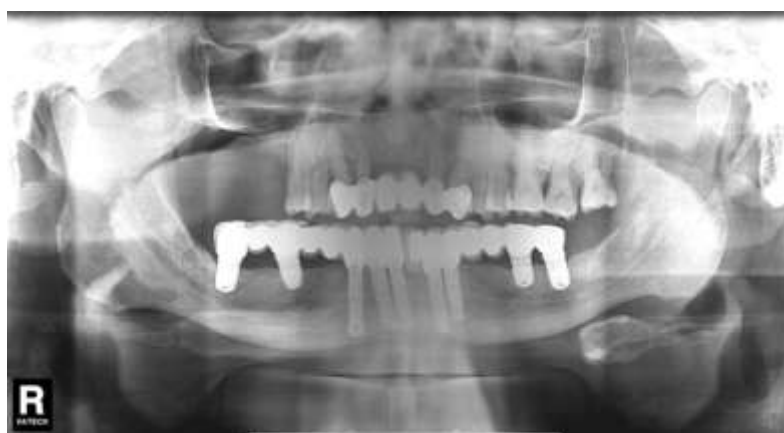Figure 2: Pre-surgical implant planning using CT scan and Simplant program software



**Figure 3:** Immediate postoperative panoramic radiograph    **Figure 4:** Three months postoperatively



**Figure 5:** Postoperative panoramic radiograph (two years after loading)

#### IV. Discussion

Placement of dental Implant in fresh extraction sockets has been reported in several recent publications (8, 9). Nevertheless, there is little information in the literature about the outcome of dental implants therapy including immediate implants in patients with diabetes mellitus. The prime factor determining the success of immediate placement is the initial stability of the implant. It has been suggested that the implant should be placed into a minimum of 3 mm of solid bone apical to the extraction site (10). In the present case, five long implants of 16 mm were inserted in the anterior region of the mandible (about 6 mm inside the socket and 10 mm apical to the socket). The follow up period showed very promising results. The insertion of long implants and the adequate implant-bone contact may explain the positive outcome of the treatment. Therefore, sufficient height and width of bone should be considered as a selection criteria for this treatment modality(10). Also, evaluation of bone density prior to surgery should not be overlooked.

Researched showed that type 1 diabetes produces a reduction in bone mineral density through mechanisms that has been attributed to both a lower formation of bone and also to a greater bone resorption (5) . On the other hand, this alteration has not been demonstrated in patients with type 2 diabetes (11). It is worth mentioning here that our patient was a well-controlled type 2 diabetic patient and the bone density of the anterior mandibular region was reasonable (D3). Moreover, although extraction of lower anterior teeth and immediate implantation in the present case were performed without the use of covering membranes and/or graft materials, the follow up period showed good osseointegration between the dental implants and the surrounding bone. Research showed that the reduction in the levels of bone-implant contact confirms that diabetes inhibits osseointegration (5). This situation may be reversed by treating hyperglycaemia and maintaining near-normal glucose levels.

On the other hand, the posterior implants performed in the present case were inserted to a depth of 7 mm only within bone to avoid injury of the inferior alveolar neurovascular bundle. Therefore, the remaining exposed parts of the implants were grafted with bovine anorganic hydroxyapatite and covered with a resorbable collagen barrier membrane. Unfortunately, panoramic x-rays showed bone resorption around the posterior implants most of which occurred during the initial healing period before loading. Similar to our findings, a prospective study of 89 well-controlled type 2 diabetics with a total of 178 implants revealed early failure rates of 2.2% (4 failures) that increased to 7.3% (9 further failures) one year after placement, indicating a survival rate of 92.7% within the first year of functional loading (12). Crestal bone resorption around the posterior

implant during the initial healing period (before loading) can be attributed to subperiosteal flap reflection during drilling and implants placement (13). Nidhin et al. (13) evaluated crestal bone levels following implant placement with flap and flapless techniques in a posterior edentulous areas of the mandible. The authors found that the crestal bone loss on the implants placed with flapless method was significantly low compared to those placed using conventional flap method (13).

## V. Conclusions

In conclusion, this case report confirms that dental implantation is a good treatment modality for well-controlled diabetic patients. Moreover, good osseointegration and increased survival rate in diabetic patients can be achieved through using immediate implants in fresh extraction sockets especially in the anterior mandibular region.

## References

- [1]. Al-Shamiri HM, Elfaki S, Al-Maweri SA, Alaizari NA, Tarakji B. Development of Nasopalatine Duct Cyst in Relation to Dental Implant Placement. *North American journal of medical sciences*. 2016;8(1):13-6.
- [2]. Javed F, Romanos GE. Impact of diabetes mellitus and glycemic control on the osseointegration of dental implants: a systematic literature review. *Journal of periodontology*. 2009;80(11):1719-30.
- [3]. King GL. The role of inflammatory cytokines in diabetes and its complications. *Journal of periodontology*. 2008;79(8 Suppl):1527-34.
- [4]. American Diabetes Association . (2) Classification and diagnosis of diabetes. *Diabetes care*. 2015;38 Suppl:S8-s16.
- [5]. Oates TW, Huynh-Ba G, Vargas A, Alexander P, Feine J. A critical review of diabetes, glycemic control, and dental implant therapy. *Clinical oral implants research*. 2013;24(2):117-27.
- [6]. Saini R, Al-Maweri SA, Saini D, Ismail NM, Ismail AR. Oral mucosal lesions in non oral habit diabetic patients and association of diabetes mellitus with oral precancerous lesions. *Diabetes research and clinical practice*. 2010;89(3):320-6.
- [7]. Al-Maweri SA, Ismail NM, Ismail AR, Al-Ghashm A. Prevalence of oral mucosal lesions in patients with type 2 diabetes attending hospital universiti sains malaysia. *The Malaysian journal of medical sciences : MJMS*. 2013;20(4):39-46.
- [8]. Chen ST, Darby IB, Reynolds EC, Clement JG. Immediate implant placement postextraction without flap elevation. *Journal of periodontology*. 2009;80(1):163-72.
- [9]. Fugazzotto PA. Implant placement at the time of mandibular molar extraction: description of technique and preliminary results of 341 cases. *Journal of periodontology*. 2008;79(4):737-47.
- [10]. Cochran DL, Schenk RK, Lussi A, Higginbottom FL, Buser D. Bone response to unloaded and loaded titanium implants with a sandblasted and acid-etched surface: a histometric study in the canine mandible. *Journal of biomedical materials research*. 1998;40(1):1-11.
- [11]. Tuominen JT, Impivaara O, Puukka P, Ronnema T. Bone mineral density in patients with type 1 and type 2 diabetes. *Diabetes care*. 1999;22(7):1196-200.
- [12]. Olson JW, Shernoff AF, Tarlow JL, Colwell JA, Scheetz JP, Bingham SF. Dental endosseous implant assessments in a type 2 diabetic population: a prospective study. *The International journal of oral & maxillofacial implants*. 2000;15(6):811-8.
- [13]. Nidhin R GK, Ajay O, Biji K. Comparative evaluation of crestal bone levels following implant placement with flap and flapless techniques in posterior edentulous areas of the mandible. An in vivo study. *IOSR Journal of Dental and Medical Sciences*. 2014;13(8):95-9.